

A CONTRIBUTION

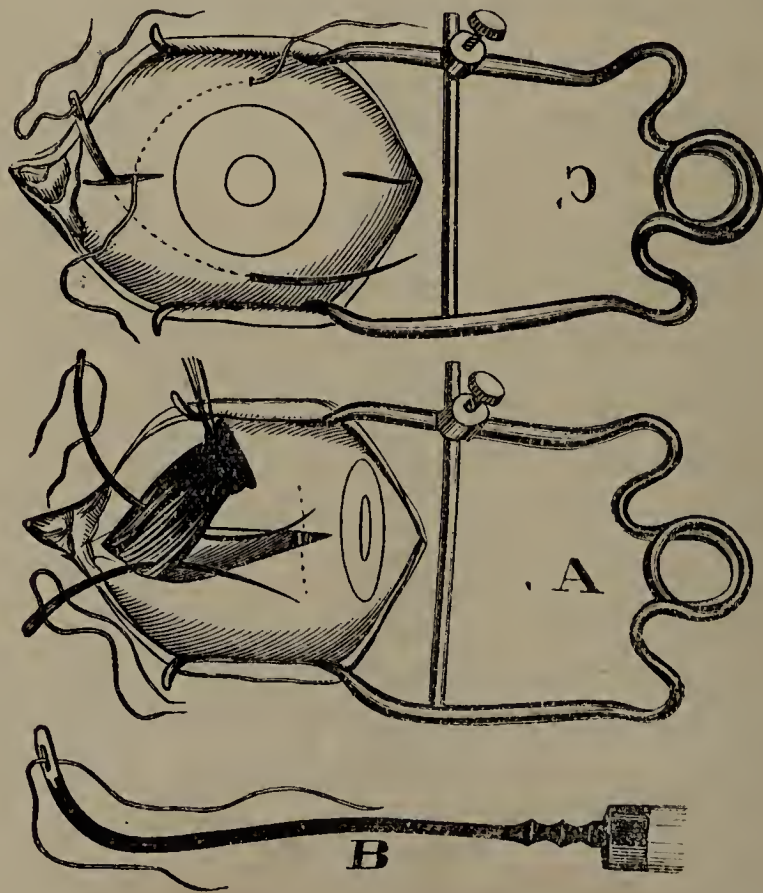
TO THE

SURGERY OF DIVERGENT SQUINT.

BY C. R. AGNEW, M. D., NEW YORK.

We are commonly asked to operate in cases of divergent squint, either to remove the deformity or relieve the dragging pain and weariness, which the loss of muscular co-ordination seems to induce. While we may certainly remove the deformity and the asthenopia, we must not expect, in the majority of cases, to restore binocular vision. The danger from inflammation is slight if the surgeon is gentle in his manipulations, and handles the parts involved with due skill. We must first determine, in a given case, whether the divergence can be corrected by a contemporaneous tenotomy of both external recti muscles, without an advancement of one or both internal recti. When an externus is successfully cut, it slips backward and adheres to the sclerotic at a point posterior to its natural insertion, and this practically increases the adductive power of the internus. Such a procedure may be successful in cases of weakness of the interni, in which the sharpness of vision in both eyes is nearly the same, but it cannot be depended upon in cases of divergent squint resulting from a tenotomy of one or both interni for previous convergent squint, nor in any case in which binocular vision has been long disturbed, and in which there is a permanent and visible divergence, however small. In such cases the faulty internus must be shortened or its line of insertion planted in the sclerotic, as close to the corneal edge as practicable and additional adductive power also given by tenotomy of the opposing externi. We will, after these few preliminary remarks, describe a method of operating which may be made to meet any or all of the indications, and the performance of which does not involve extraordinary skill, or subject the eye to the danger of grave inflammation.

The method illustrated by the cuts A, B, and C, is one in which the internus is detached from its sclerotic insertion, drawn forward, shortened and made to adhere again to the sclerotic, without attempting to lift and advance the overlying conjunctiva and capsule of Tenon. The patient having been profoundly etherized, and the eye to be operated upon held open by means of a spring speculum, an incision is made from the nasal end of the horizontal meridian of the cornea, back through the semilunar fold to the caruncle. This incision is best made with scissors, and should be carried down through the conjunctiva and capsule of Tenon upon the internus midway between its borders. The externus of the same eye should now be divided, access being made to its insertion through a conjunctival wound tangent to the cornea, as in cut C. This can be easily done without cutting off, in any degree, the nutrition of the cornea, as is the case where the wound is made parallel to the corneal border. The next step is to get control of the internus so that it can be easily handled. This is accomplished, not by forceps, but by using a strabismus hook as figured in B. The free end of the hook, drilled with an eye and




armed with a waxed ligature, is made to pass as one would pass an ordinary hook beneath the tendon, going so far back as to secure any adventitious bands. As the hook is withdrawn, the ligature is left in place, and the tendon, at its sclerotic insertion, firmly tied. With scissors, the tendon is then detached from the sclerotic and drawn out of the wound as delineated in cut A. Two sutures for the advance-

ment of the muscle are then placed, as in cut A, by curved needles, handled by some convenient needle-holder, like that of Prof. Sands. The sutures, well waxed, should transfix the muscle at as great a distance from the end of the tendon, as the degree of the divergence would seem to require. It is difficult to make an inflexible rule for this, but we have commonly found that the distance should be about one-fourth greater than the linear measurement of the divergence, except in cases where said divergence exceeds four lines, in which event, the needles should transfix the muscle as far back as the caruncle will allow. The sutures having been placed in the muscle, the next step is to carry them beneath the conjunctiva, and, if possible, beneath the capsule of Tenon, and out above and below the cornea at the termini of its vertical meridian. Cut C, shows the needle in the course of the lower suture, and the upper suture in place. It now remains to cut off the end of the tendon, as held in the ligature, leaving a line or two of muscular tissue to prevent the sutures from tearing out, and to tie first the upper suture and then the lower one with such manipulations as would serve to spread out the advanced tendon beneath the corneal end of the conjunctival wound, and over that portion of the sclerotic to which it is hoped it will adhere. The eye should be strongly and accurately adducted during these manipulations, by catching the scleral remains of the cut tendon of the external rectus in forceps, and so turning the cornea, without tilting its horizontal meridian, well over into the internal canthus.

I have, commonly, also divided the external rectus of the fellow eye, in cases in which the divergence exceeded three lines, especially when the adductive power of the interni was greatly weakened.



There is, commonly, considerable reaction after the operation, but it is easily controlled by cold applications. It now remains to give some cases illustrative of the operation, without going into prolonged descriptions.





The preceding cuts, taken from photographs, show the case of a young lady who had had amblyopia of a high degree from childhood, and progressive divergent squint. It was not expected that vision would be improved, the operation being undertaken to remove the deformity, and to relieve a constant sense of fatigue in the eyes. The internus of one eye was advanced by the method described, and both externi were cut.

The following cuts show a case in which a wandering oculist had divided both interni, at the same sitting, for convergent squint. The divergence was about five lines, and the sinking of the caruncle was



marked. The eye most affected was very amblyopic, and had mixed astigmatism. The fellow eye was emmetropic, and its vision normal; internus of worst eye advanced; both externi divided; result shown.

Cases might be multiplied, but already we have exceeded the limits fixed by us when we began the narrative. At some future time, we may trespass upon the society to describe another method for the cure of divergent squint, for which we have numerous illustrations.

